

---

Neodent®

Helix GM® Long Implants  
SURGICAL MANUAL

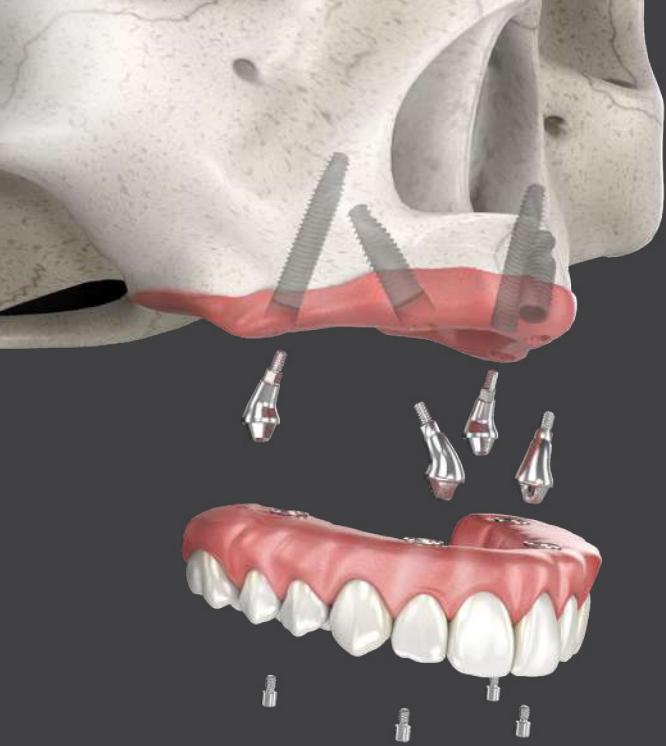*GRAND MORSE®*



# CONTENTS

---


- NEODENT® HELIX GM® LONG ..... 4**
  
- PRE-OPERATIVE PLANNING .....5**
  - Anatomical Considerations ..... 5
  - Digital 3D Planning ..... 9
  - Implant Distribution and Prosthesis Definition ..... 9
  
- LONG IMPLANTS.....11**
  - Helix GM® Long implants - solution for bicorticalization ..... 11
  - Surgical procedures and implant placement ..... 12
  - Prosthetic options and procedures ..... 14
  
- HELIX GM® LONG IMPLANT PACKAGING ..... 20**
  
- COMPREHENSIVE RESTORATIVE SOLUTIONS:  
DESIGNED TO MEET THE PATIENTS’ EXPECTATIONS ..... 21**
  
- FOLLOW-UP ..... 22**
  - Cleaning and Care ..... 22
  
- REFERENCES ..... 23**



— Immediate solution in severe atrophic maxilla

The Neodent® Helix GM® Long complement the standard implant system for achieving immediate loading protocols in fixed full-arch restoration. They are specifically designed to bring surgical predictability to atrophic maxilla cases, as an alternative to grafting procedures.

Helix GM® Long  
Solution for bicorticalization



**1. GRAND MORSE® CONNECTION**

- All benefits of the original 16° Morse taper GM connection designed to ensure a tight fit for an optimal connection seal.
- One connection regardless of the diameter.

**2. IMPLANT DESIGN**

- Helix® hybrid implant body to maximize treatment options and efficiency.
- Dynamic progressive threads, designed to achieve high primary stability.

**3. COMPREHENSIVE PORTFOLIO**

- 3.75 and 4.0 mm diameters for more treatment versatility.
- 20, 22.5 and 25 mm lengths designed to achieve bicorticalization.

NeoPoros

# PRE-OPERATIVE PLANNING

## 1. Anatomical Considerations

Prosthetic rehabilitation starts with a clear and previously-defined prosthetic plan, developed according to the patient's remaining structures, including residual alveolar bone and smile line.

Note: Full-arch restoration is presented as an example throughout this manual--the zygoma implants are also indicated for partial-arch applications.

### Residual Alveolar Bone

The residual alveolar ridge undergoes physiological resorption after tooth loss (Fig 1). This resorption can be located in different zones in the arch. Patients presenting atrophic conditions are indicated to receive fixed full-arch rehabilitations. The use of implants becomes important to retention and stability of the entire system.

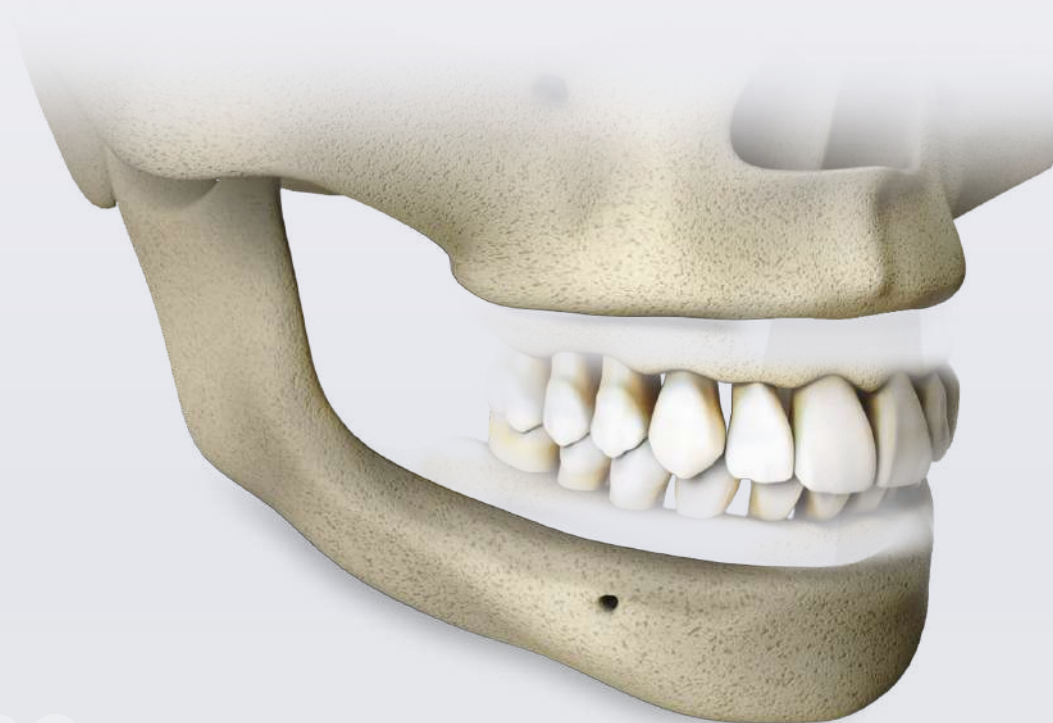
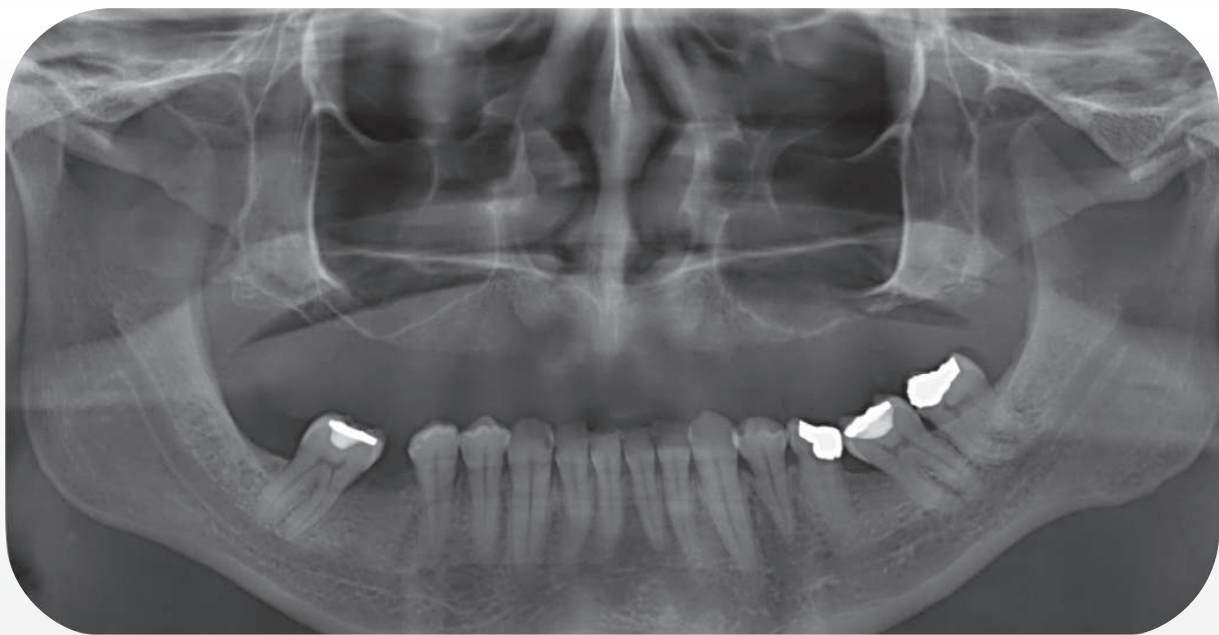


Fig 1. Mandible and maxilla bone resorption after complete tooth loss.

The maxilla has a lower bone density than the mandible, especially when compared at the anterior mandible region between the mental foramen region. Therefore, bicorticalization is a good method to achieve high primary stability of implants in the maxilla. In addition, Helix LG implants can be an effective strategy to enhance contact area with remaining bone avoiding anatomical challenging structures and allowing bicorticalization (Fig 2). At the same time, anterior implants are limited by the nasal cavity and sometimes can be placed in a tilted fashion, also with the apex distally angled, which results in the same benefits, and is known as the M-4 treatment<sup>(1)</sup>.



\* Patient treatment data authorized for publication.

Fig 2. Sinus and nasal cavity walls might present higher bone density for positioning the implants.

## Smile Line

The patient's smile line determines the esthetic challenges that will drive important surgical and prosthetic procedures when the aim is a natural looking solution. Both characteristics, the smile line combined with the residual alveolar ridge height, (Fig 3) dictate bone horizontal osteotomy, implant positioning and prosthetic extension (with or without "pink esthetic") based on esthetics space for the restoration, and hygiene of the final prosthesis.

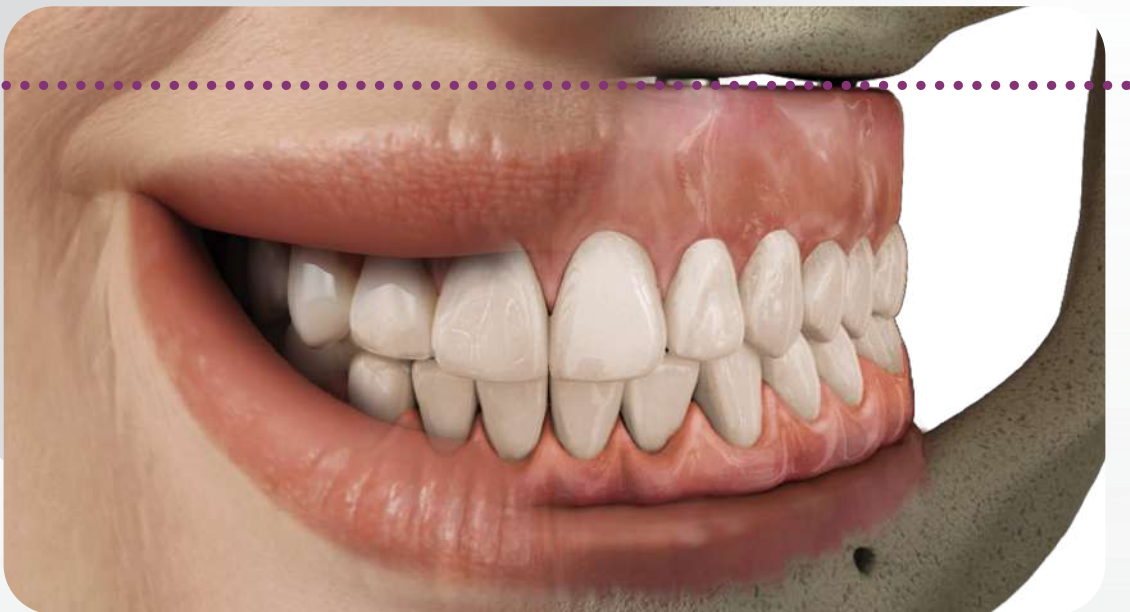


Fig 3. Rehabilitation extension according to patient's structures.

The upper lip defines the patient's smile line and the contact between bridge and remaining mucosa should never be exposed, otherwise there will be esthetic problems in the final restoration. The upper lip must cover the transition line between bridge and remaining mucosa independent of the residual bone structure.

During the planning stage, it is important to evaluate the volume of patient's residual alveolar bone.

## VOLUME OF RESIDUAL ALVEOLAR BONE







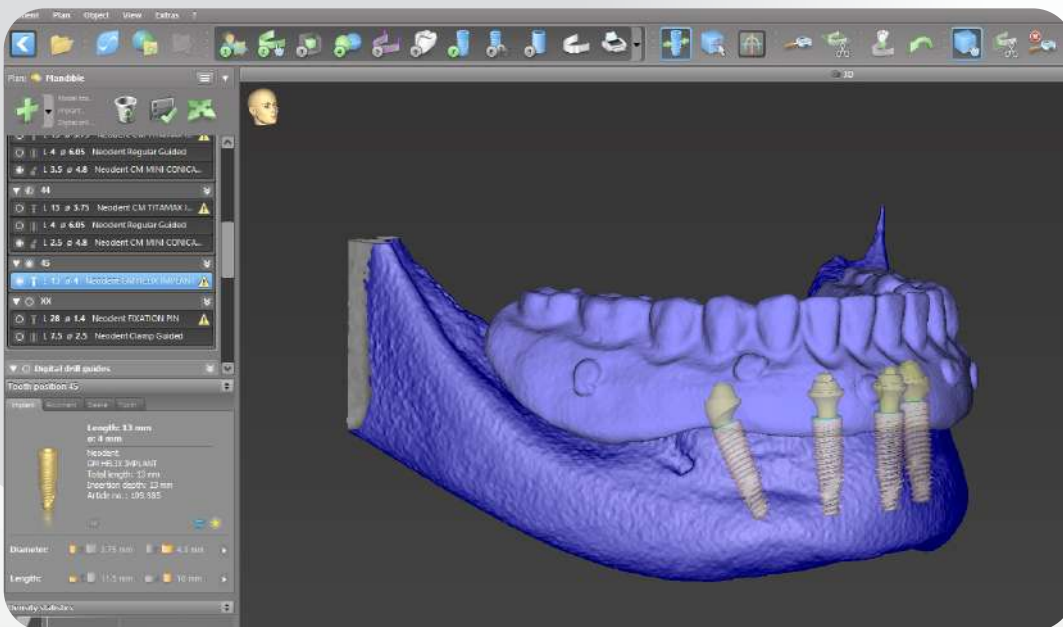
	small	mid	high
<b>BEFORE</b>			
<b>Indication for horizontal osteotomy</b>	Not indicated if the bone is in harmony with the upper lip and even.	Indicated to flatten the bone to avoid esthetic and functional problems.	Not indicated if the bone is in harmony with the upper lip and there is prosthetic space for the restoration (see also smile line).
<b>Smile Line High</b>	No osteotomy if the remaining bone is parallel to the upper lip, even and covered by the upper lip.	No osteotomy if the remaining bone is parallel to the upper lip, even and covered by the upper lip.	No osteotomy if the remaining bone is parallel to the upper lip and even. Osteotomy is only indicated if the remaining bone isn't in harmony with the upper lip.
<b>Smile Line Low</b>	No osteotomy if the remaining bone is even.	No osteotomy if the remaining bone is even.	No osteotomy if the remaining bone is covered under the upper lip, even and there is space for the prosthesis.
<b>AFTER</b>			
<b>Type of restoration</b>	Large amount of pink esthetic in the restoration.	Small amount of pink esthetic in the restoration.	No pink esthetic.

Table 1. Previously uneven smile line between crowns and mucosa due to bone extrusion and smile line after osteotomy for fixed full-arch rehabilitation.

## 2. Digital 3D Planning

For a successful full-arch rehabilitation, the initial prosthetic planning constructed with the aid of a tomography guide according to proper occlusion using Cone Beam Computed Tomography (CBCT) images will define the proper position of implants, and takes into consideration anatomical structures, especially for complex rehabilitation (Fig 4). If the patient presents a well-established conventional complete denture, it also can be used as a guide and as an immediate provisional implant-supported prosthesis. In addition, specific planning software can be used to determine implant positions.



\*Data extracted from coDiagnostiX™ software.  
\*Patient treatment data authorized for publish.

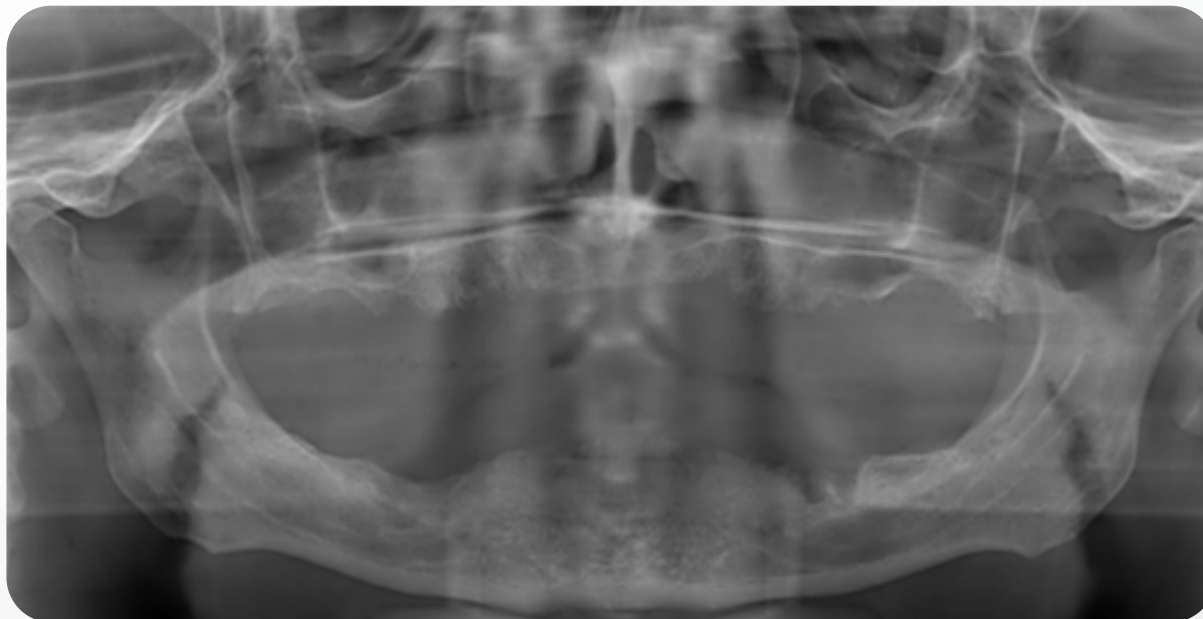
Fig 4. Implant distribution according to bone availability and prosthetic planning.

## 3. Implant Distribution and Prosthesis Definition

Implant distribution is an important factor to be considered in full-arch bridges as it supplies mechanical result on the system. Anteroposterior implant placement and occlusion should be balanced to avoid stress concentrations<sup>(1)</sup>. Bone condition, such as density, thickness, and anatomical structures are responsible for the implant distribution planning. Therefore, the posterior maxilla is considered the most difficult and problematic intraoral area for treatment with osseointegrated implants, presenting deficient bone quality and quantity, surgical access, and biomechanics (greater masticatory forces)<sup>(2,3)</sup>.

For extremely atrophic ridges in maxillary bone, implant placement in denser cortical bone such as zygomatic regions can provide adequate implant support and eliminate procedures such as sinus augmentation, supplemental bone block grafts, and the use of a large number of implants<sup>(4,5)</sup>.

Clinicians can define implant distribution based on the size of the cantilever where distal implants are initially determined. The medial implants can then be placed as far anterior as possible to spread the implants along the arch and distribute forces equally across the entire arch and implants.



\*Patient treatment data authorized for publication.

Fig 5. Panoramic radiography of an edentulous patient.

Note: Anterior/posterior implant distribution on the arch should be carefully evaluated because this determines stress distribution of the system.

Distal implants should be placed before anterior implants as they determine the posterior limits of implant distribution and are closer to key anatomical structures that must be avoided, such as the nasal cavity and sinus for the maxilla. Because the posterior tilted implants installation occurs around the 1st and 2nd pre-molar region, a short cantilever is indicated to extend until the 1st molar, which decreases stress on the peri-implant cortical bone and increases the rehabilitation's longevity. Therefore, the prosthesis should extend to a maximum of 12 teeth.

## 2 LONG IMPLANTS

Neodent® Helix LG Long implants are intended to be surgically placed in the maxilla bone providing support for prosthetic rehabilitations, restoring patient chewing function. They may be used with single-stage or two-stage procedures, for multiple unit restorations, and may be loaded immediately when proper primary stability is achieved and with appropriate occlusal loading. They are indicated for rehabilitation of patients with an atrophic maxilla.

### — Helix GM® Long implants - solution for bicorticalization

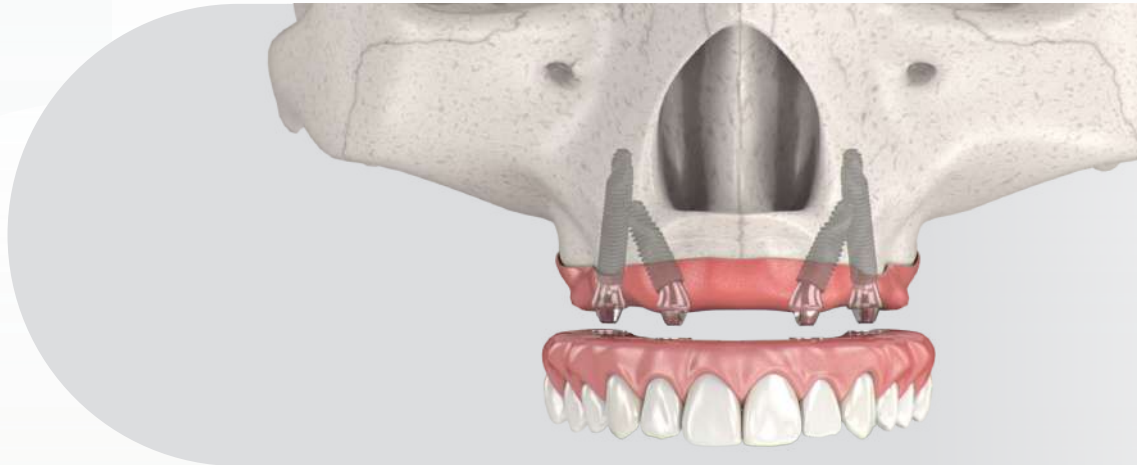


Fig 6. Implant positioning on a full-arch rehabilitation with 2 long implants and 2 regular implants.

- GM prosthetic connection;
- Diameters of 3.75 and 4.0 mm;
- Lengths of 20.0; 22.5 and 25 mm;
- Interface aligned to the implant longitudinal axis;
- Neoporos surface.




Ø3.75	109.1043	109.1044	109.1045
Ø4.0	109.1046	109.1047	109.1048

Table 2. Helix GM® Long implant lengths and diameters.

## Surgical procedures and implant placement

The technical approach for long implant placement is similar to regular size implants. The awareness of anatomical structures and corticalization of such implants, on lateral bone tables of nasal cavity, maxillary sinus, or pterygomaxillary plates region turn to be extremely important, once the extension of such implants is higher. Additionally, the use of longer drills and instruments is required.

The drills of Helix GM® Long are used surgically in the perforation of bone tissue during bed preparation in cases of atrophic maxilla. The set for implant placement is formed by seven drills. Among them, there are three for guided surgical procedure and four for the conventional procedure.



	Initial	Ø2.35*	Ø3.75*	Ø4.0*
	103.453	103.462	103.463	103.464
Ø3.75 mm	Optional	✓	✓	
Ø4.0 mm	Optional	✓	✓	✓

For bone types III and IV

\* Drills available for both conventional and Guided Surgery procedures.

Table 3. Helix GM® Long drill sequence.

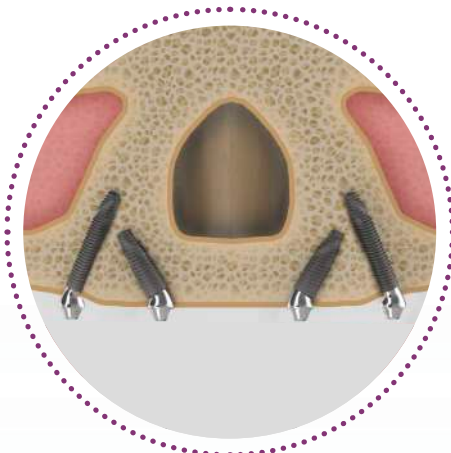


Fig 7.

Four implants are used, two posterior and two anterior (Fig 7). The two posterior implants are installed in the pre-molar position, in a direction that is inclined up to 45° in a mesial direction tangent to the anterior wall of the maxillary sinus, with the prosthetic platform appearing at the position of the 2nd premolar or 1st molar. The two anterior implants are tilted posteriorly to also cover the lateral border of the pyriform<sup>(9,23)</sup>.

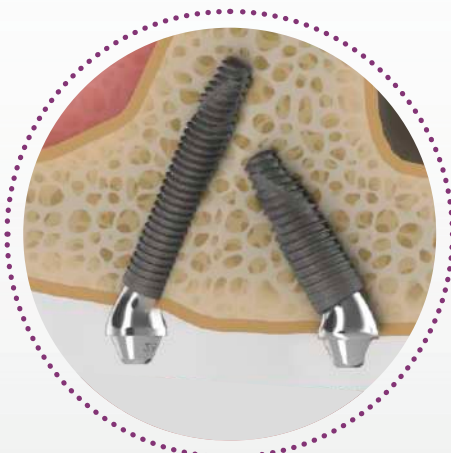


Fig 8.

The M Point is the maximum bone mass at the lateral pyriform rim above the nasal fossa, where the implant apices can engage cortical bone for primary stability<sup>(9,23)</sup> (Fig 39). Usually this is an area that does not resorb in the maxilla.

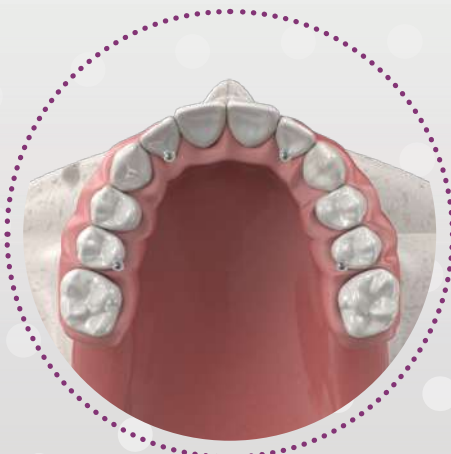

Fig 9.

According to Jensen et al. (2014) the most favorable implant angulation, surgically and prosthetically, is 30 degrees, based on the following 3 points:

1. Length of the implant in bone increasing by 50%;
2. It increases occlusal load resistance;
3. Leads to sub-osseous conformation is splinted configurations, increasing the resistance to shear force (Fig 9).

## Prosthetic options and procedures

### Abutment selection, provisional, and final restoration

After the Helix GM® Long implants have been placed, abutments are then chosen. The provisional prosthesis and final prosthesis present a similar workflow to the technique used for regular sized implants.

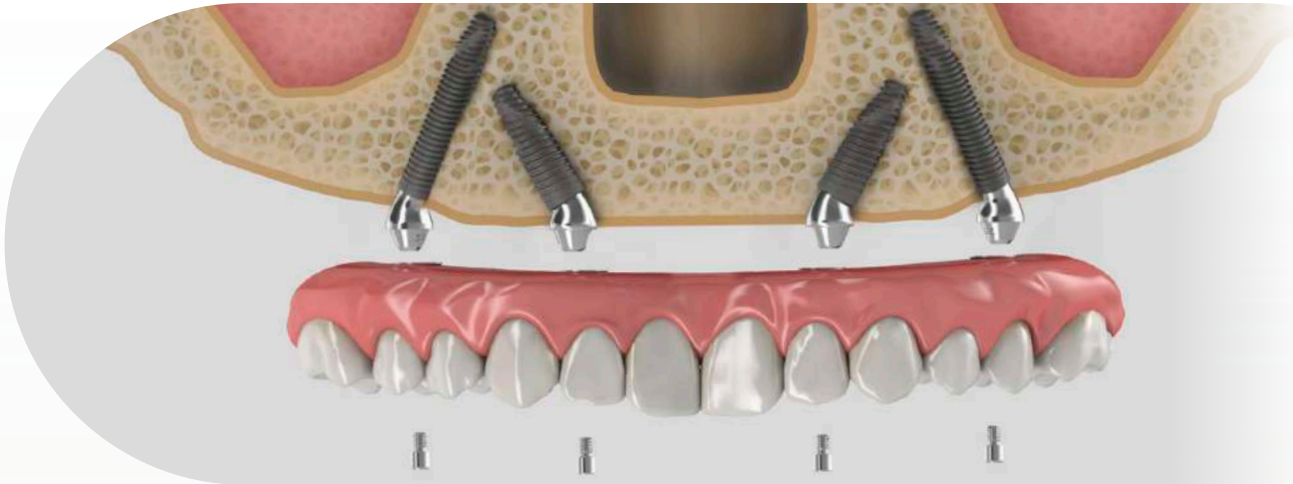


Fig 10. Depending on the implant placement position and the residual alveolar ridge arch, straight or angled abutments are selected.

#### GM Exact Mini Conical Abutment



	17°	30°
1.5 mm	115.249	115.252
2.5 mm	115.250	115.253
3.5 mm	115.251	115.254

Table 4. GM Angled Mini Conical Abutment.

#### GM Angle Measurer



	17°	30°
	128.032	128.033

Table 5. GM Angle Measurers.

Once the surgical and abutment placement procedures are completed, an impression is taken to cast the final abutment positions in the plaster model. The following steps for an OPEN TRAY IMPRESSION are indicated:

1. Place the Slim Mini Conical Abutment Open Tray Impression Coping accurately onto the abutment and only rotate the screw, manually or with the aid of Neo torque Connection (Fig 22). Make perforations in the custom made impression tray (light-cured resin) according to the individual situation and check if the screw of impression coping protrudes visibly.

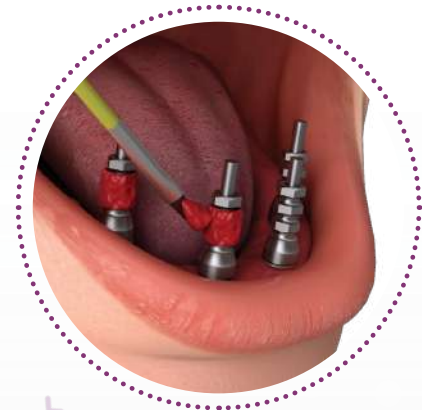

Fig 11.

2. Splint the Impression Copings using a low shrinkage polymerization acrylic resin according to the manufacturer recommendation. It is recommended to take the impression using a standard elastomeric impression material (e.g. polyvinyl siloxane). Uncover the screws before the material is set. Once the material is set, loosen the copings screws with the Neo Torque Connection and remove the tray. For easy abutment identification, include the analogs when you send the dental impression to your dental lab partner (Fig 12).

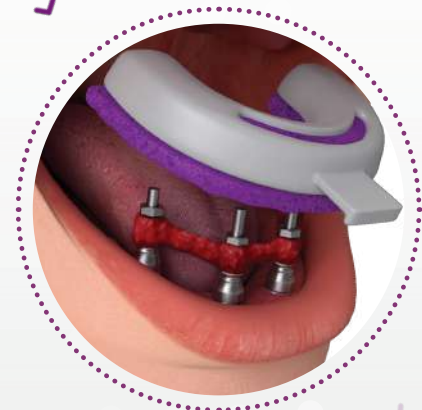

Fig 12.

3. Fabricate the master cast with stone type IV (Fig 13) or proceed with a digital scanning process creating a 3D printed model. For a conventional workflow, a gingival mask should always be used to ensure that the emergence profile is optimally contoured. This final plaster model will be used in the next steps of restoration process.

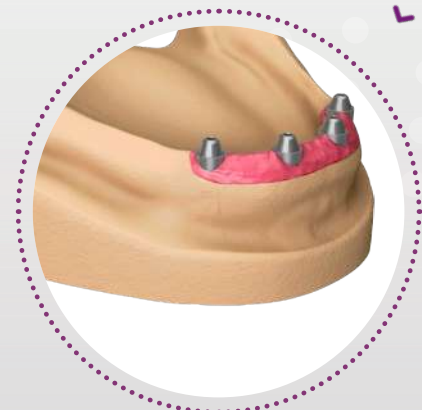


Fig 13.

## Immediate provisionalization

In the 48 hours after the surgical procedure, clinicians can provisionally restore the patient's oral function and esthetics. The restorative portfolio contains the Neo Distal Bar to strengthen the provisional transition from complete denture to fixed full-arch. The following steps for an IMMEDIATE TEMPORALIZATION are indicated:

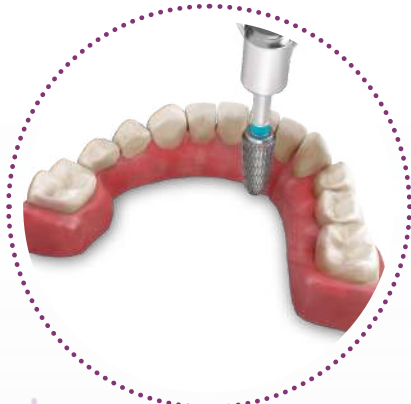


Fig 14.

1. Promote lingual wear on the conventional complete denture preserving the buccal and posterior region integrity (Fig 14).

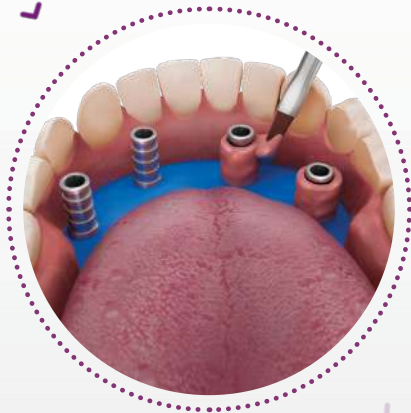


Fig 15.

2. Place non-engaging Titanium Copings on the anterior and posterior abutments. Check the alignment and relation between implant components and the prosthesis. Once the position is ensured, make sure the occlusal set up fits with the prepared prosthesis and place a rubber sheet over the copings to protect and avoid acrylic resin contact with soft tissue (Fig 15). Apply pink acrylic resin around the copings. Patient should be in occlusion to establish a proper central relation between arches until resin polymer.

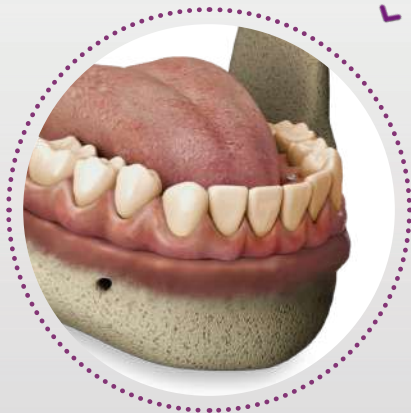

Fig 16.

3. Finalize and polish the temporary restoration. Place the temporary restoration in the patient's mouth and tighten the occlusal screws to 10 N.cm using the Neo Screwdriver (Fig 16).

After the final plaster model is produced, the bar can be made at the laboratory center by conventional cast.

1. Place the castable copings (One step hybrid set or conventional copings) on the top of the analogs with a 10 N.cm torque (Fig 17). Wax-up the bar-framework according to the availability of patient interocclusal space.

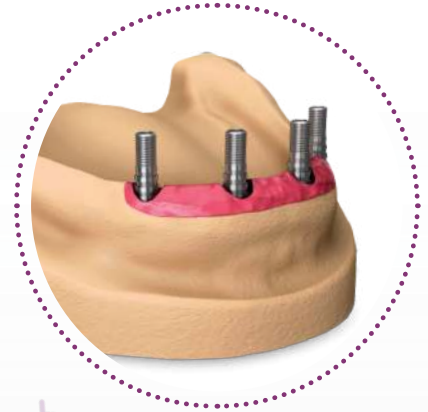

Fig 17.

2. Cast the bar and check its alignment over the model (Fig 18). For conventional casting, a clinical section is required to ensure a passive fit of the bar. If not, perform a cross-section on the bar and reconnect intraorally with low shrinkage polymerization acrylic resin, reestablishing the fit of the bar. For the One step hybrid technique, cement the structure over titanium copings.

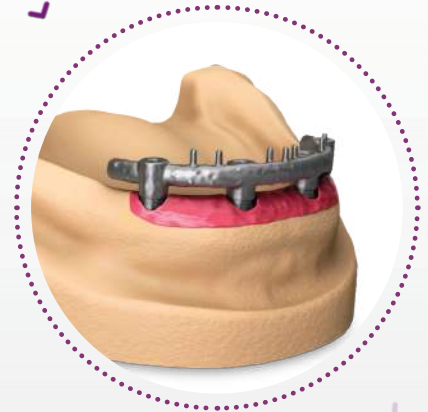

Fig 18.

3. Produce the final restoration based on the custom-milled framework. Install final complete fixed restoration on the patient's mouth (Fig 19).

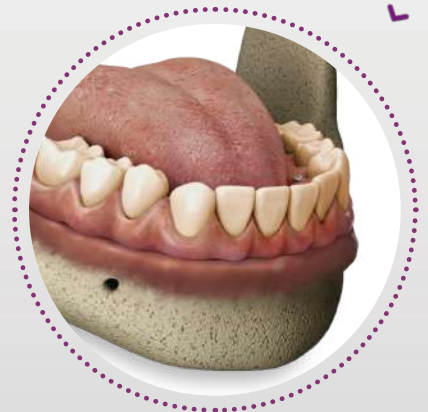

Fig 19.

If you decide to work with a custom-milled digital framework, please proceed as follows:

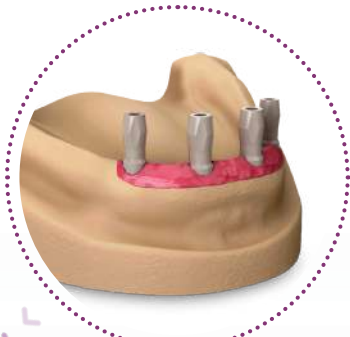


Fig 20.

1. Fabricate a master cast based on a dental impression or proceed with digital scanning process to create a 3D printed model. Place the Mini Conical Abutment Scanbodies onto the analogs on the dental model using the 1.2 Manual Screwdriver (Fig 20).



Fig 21.

2. Scan the plaster model set with the help of a scanner and design the framework in CAD software (Fig 21).

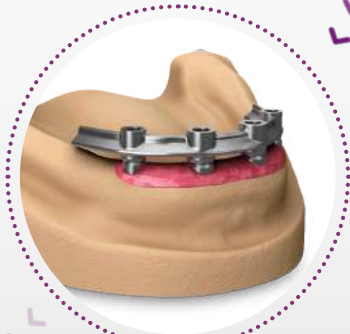


Fig 22.

3. Produce the final restoration based on the custom-milled framework (Fig 22).

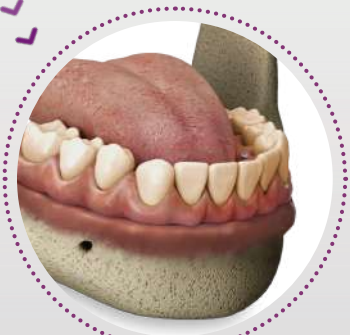

Fig 23.

4. In the dental office, place the final restoration into the patient's mouth (Fig 23).

Visit <http://en.neodent.com.br/libraries-cadcam> to download the digital Neodent® files. Libraries are available for the following softwares: CARES Visual, Dental Wings and 3Shape.

In planning for a restoration in the maxilla, the cantilever should extend only for the 1st molar. Anterior implants can be located at the lateral incisor or canine region<sup>(1)</sup> (Fig 24).

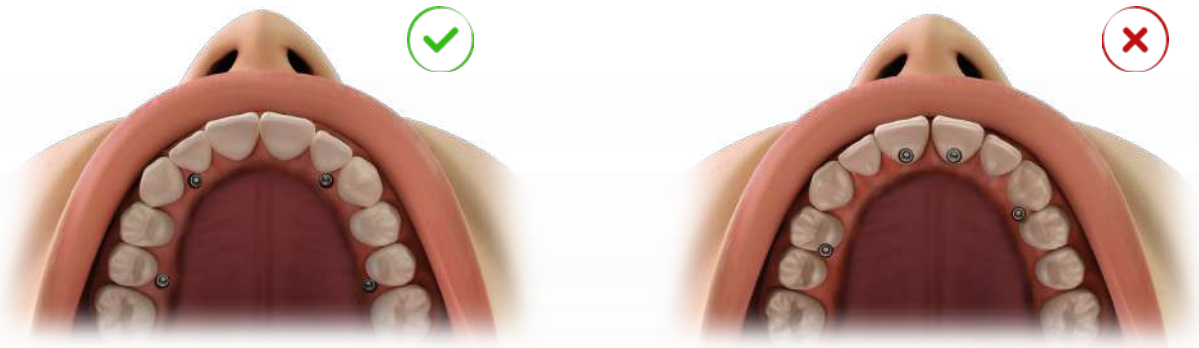


Fig 24. Proportion and relation of implants positioning and size of cantilever.

For a better stress distribution, the outlined shape between the implants should be the biggest square format as possible.

# HELIX GM® LONG IMPLANT PACKAGING

Neodent® packaging has been specially updated for easy handling, providing safety from implant stocking to the capture and transport to implant bed. The implant's features, such as type, diameter and length, are identifiable on the outside of the packaging.

Three self-adhesive labels are provided for recording in the patient's medical records and for reporting to the prosthesis team. They also allows traceability for all articles.

After opening the blister, note that the implant will remain attached at the lid. In order to break the base holder of the implant, hold the lid and apply a contra-torque with the GM Connection for contra-angle (a maximum torque of 20 N.cm). Or for manual installation, use the Zygomax GM® Implant Driver with the Neo Screwdriver Torque Connection. Finish the implant placement with the aid of the Torque Wrench.



Fig 25. Instructions for opening and carrying the implant packaging.

Note: The holder is integrated to the implant body, but is designed to be removed from the blister without any apical burr.

# COMPREHENSIVE RESTORATIVE SOLUTIONS: DESIGNED TO MEET THE PATIENTS' EXPECTATIONS

Meet patient stability and comfort expectations thanks to a comprehensive custom made milled framework for provisional or final restoration at the abutment level using a broad range of material and workflows.

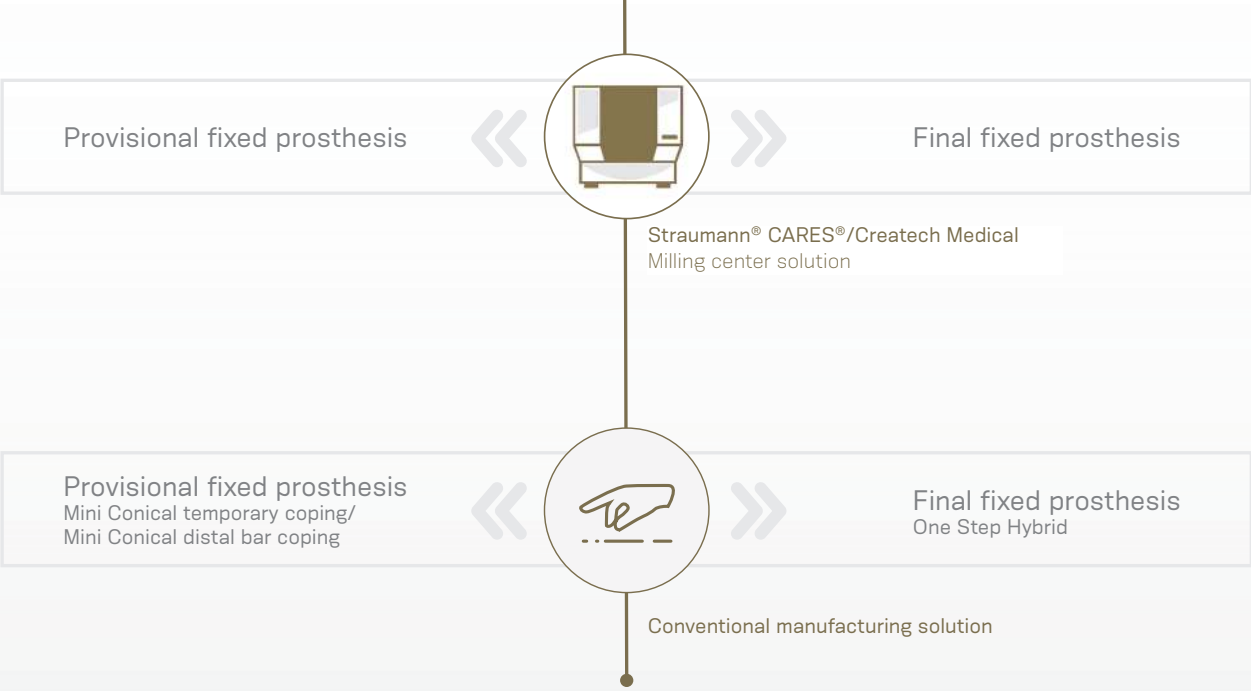


Table 6. Framework for provisional and final fixed prosthesis.

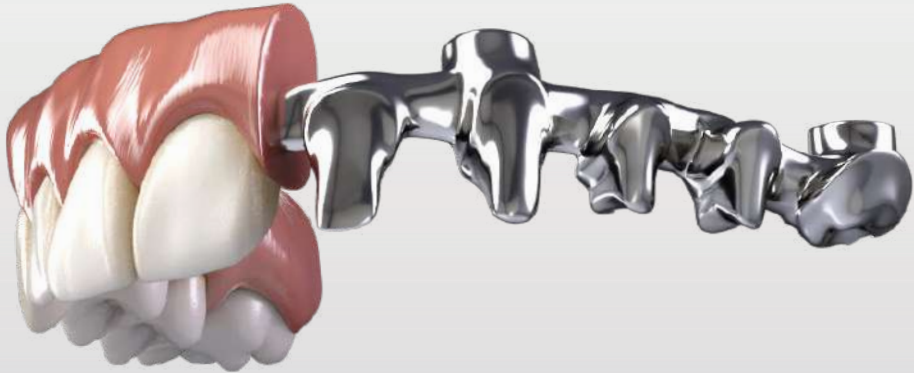

Fig 26. Illustration of final prosthesis on a milled bar.

# FOLLOW-UP

## Cleaning and Care

For long-term success and proper fit of the fixed bridge, comprehensive patient instruction and periodic check-ups (at least once a year) are recommended. During these visits, you should carefully examine the:

- 1. Condition of the peri-implant tissues with regard to oral diseases such as plaque and calculus, bleeding, recession, and bone loss, by taking regular periapical radiographs.*
- 2. Superstructure and prostheses occlusion, proper fit of the fixed bridge, wear of occlusal surface, retention, screw loosening, and abutment status.*
- 3. Function of the prostheses.*

Provide professional cleaning with the aid of ultrasonic or periodontal curettes, removing the prosthesis if necessary, and use cleaner prostheses agents. If a proper maintenance of the fixed restoration is provided, it is not necessary to exchange the occlusal screws at each check-up visit.

A full-arch prosthesis requires spaces for the framework and the esthetical veneering (can be either ceramic or acrylic). Also, from a functional point of view, full-arch bridges should allow for the patient's future hygiene and should never cover the remaining tissue, which will facilitate the patient's cleaning of the bridge.

For proper care at home, instruct the patient to clean the space between gingiva and fixed bridges, especially around the implants on a regular basis. Dental floss or interdental brushes are recommended.

# REFERENCES

---

- [1] Jensen OT, Adams MW. Secondary stabilization of maxillary m-4 treatment with unstable implants for immediate function: biomechanical considerations and report of 10 cases after 1 year in function. *Int J Oral Maxillofac Implants.* 2014;29(2):232-40.
- [2] Zarb GA, Zarb FL, Schmitt A. Osseointegrated implants for partially edentulous patients. *Dent Clin North Am* 1987;31:457-472.
- [3] Balshi TJ. Single tuberosity osseointegrated implant support for a tissue integrated prosthesis. *Int J Periodontics Restorative Dent* 1992;12:345-357.
- [4] Reiger MR. Loading considerations for implants. *Oral Maxillofac Clin North Am* 1991;3:795-804.
- [5] Balshi TJ, Wolfinger GJ, Slauch RW, Balshi SF. Brånemark system implant lengths in the pterygomaxillary region: a retrospective comparison. *Implant Dent.* 2013;22(6):610-2.
- [6] Stella JP, Warner MR. Sinus slot technique for simplification and improved orientation of zygomatic dental implants: a technical note. *Int J Oral Maxillofac Implants.* 2000;15(6):889-93.
- [7] Agliardi, E. L., Romeo, D., Panigatti, S., de Araújo Nobre, M., & Maló, P. (2017). Immediate full-arch rehabilitation of the severely atrophic maxilla supported by zygomatic implants: a prospective clinical study with minimum follow-up of 6 years. *International journal of oral and maxillofacial surgery*, 46(12), 1592-1599.

© Neodent® 2020. All rights reserved.  
Neodent® and/or other trademarks and logos  
from Neodent® that are mentioned herein are  
the trademarks or registered trademarks of  
Straumann Holding AG and/or its affiliates.

® All other trademarks are the property of  
their respective owners. All rights reserved.

[ifu.neodent.com.br/en](http://ifu.neodent.com.br/en)  
[www.neodent.us](http://www.neodent.us) • [www.neodent.ca](http://www.neodent.ca)



Straumann North American Headquarters  
Straumann USA, LLC  
60 Minuteman Road  
Andover, MA 01810  
Phone 800/448 8168 (US) • 800/363 4024 (CA)  
Fax 978/747 2490  
[www.straumann.us](http://www.straumann.us) • [www.straumann.ca](http://www.straumann.ca)

NAMLIT.2062 1/20 V1 PMR

